

Intratympanic/Transtympanic Gentamicin Treatment for Meniere's Disease

[Timothy C. Hain, MD](#) Page last modified: September 12, 2015

<http://www.dizziness-and-balance.com/treatment/ttg.html>

[TTG/ITG defined](#) [procedures](#) [Where to get it done](#)

The situation has changed greatly with gentamicin treatment in the last few years -- this document has recently been updated to reflect the very good results that have been obtained with a newer protocol - -low dose gentamicin.

Intratympanic gentamicin (ITG) and Transtympanic gentamicin (TTG) defined

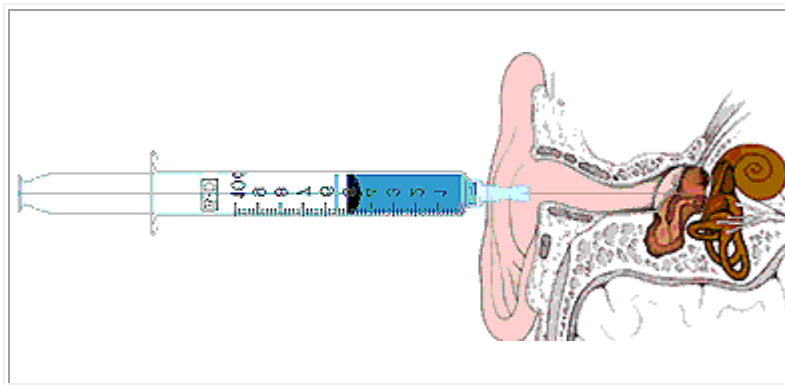


Figure 1. Gentamicin (a medication intended to purposefully damage the inner ear to stop dizzy spells in Meniere's disease) is injected through the eardrum using a narrow needle. The drug is left in the middle ear for 30 minutes, and then allowed to drain out.

In severe cases of episodic vertigo, such as due to [Meniere's disease](#), treatments that deaden the inner ear such as gentamicin injections may be considered. This is usually a last resort treatment for persons who have severe attacks of vertigo. Injections of gentamicin are given through the ear drum, by way of a small needle. This is called "intratympanic gentamicin treatment". Some authors call the same process "transtympanic gentamicin" (e.g. Casani, Nuti et al. 2005), but the "intratympanic" term seems to be much more popular.

This procedure allows one to treat one side, without affecting the other. For many years multiple doses of gentamicin were used - - typically 4-6 injections over a few weeks to months. While this "high dose" gentamicin protocol was very effective, it was accompanied by major side effects - - a substantial risk of hearing reduction, and often a prolonged period of dizziness and vertigo induced by the treatment itself. We do not recommend this procedure anymore due to the collateral damage.

Recently, the "low dose" protocol with just one or two injections in total spaced 1 month apart, has become the standard. The procedure is not (very) painful -- a [local anesthetic](#) is used to numb the ear drum. A drop of phenol on the ear drum is one method. Another is a topical anesthetic such as "Emla" cream. The drug is injected, left in the middle ear for 30 minutes while the person is lying quietly, and then an attempt is made to clear it from the

middle ear via the ET tube (with swallowing and "popping" the ear). This last step is probably important to obtain reproducible results.

Disability is lessened in patients with Menieres after TTG treatment (Pfleiderer, 1998; Perez et al, 1999). Dizziness may reoccur one year later, requiring another series of injections. Several authors have reported that tinnitus or fullness may improve substantially after TTG (e.g. Sala, 1997), but this cannot be counted upon. The long-term effect on hearing is presently unclear. It would seem most likely that it accelerates hearing loss.

A substantial advantage of TTG treatment is low cost, compared to alternative destructive treatments (i.e. [vestibular nerve section or labyrinthectomy](#)). Most authors find that the control of vertigo is comparable to vestibular nerve section (about 90%). TTG treatment is also intrinsically of very low risk, especially compared to nerve section. Compared to labyrinthectomy, TTG treatment is also lower in risk because there is no need for general anesthesia.

ITG/TTG has been advocated for other vestibular disorders than Meniere's disease (e.g. Brantberg et al, 1996). At this writing (2009), in our opinion this use should be a "last resort".

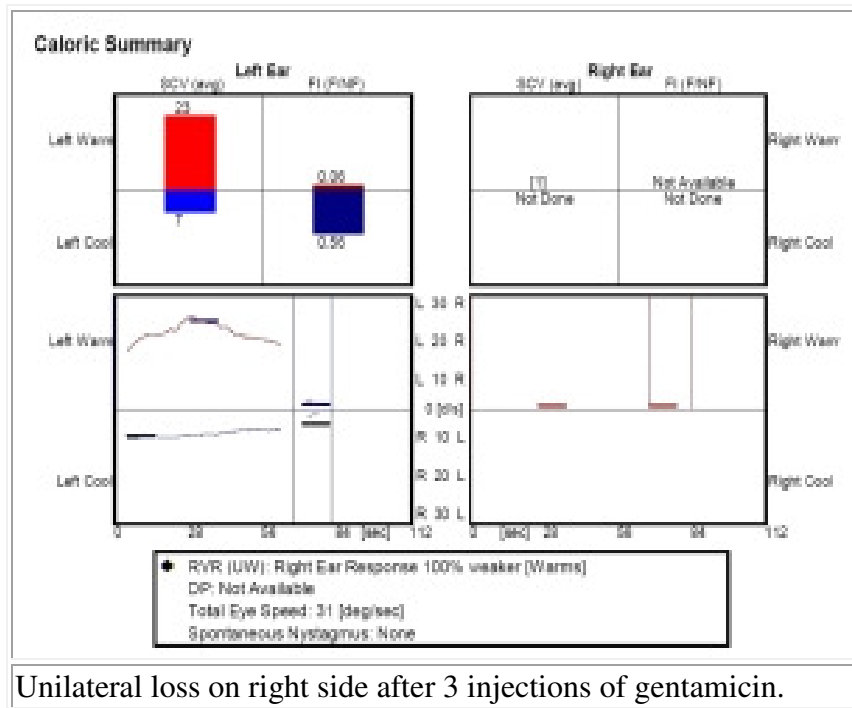
Two main variants of ITG/TTG:

[Technical details of injecting gentamicin are given here.](#)

Low dose -- our preference

The low dose method involves using 1-2 injections of gentamicin, waiting a month between injections. This variant stops vertigo 66-80% of the time, with no significant side effects at all. The low dose variant is relatively new, and there is not nearly as much data concerning outcome as the high-dose variant.

The 2nd injection is given only if there has been a vertigo spell in the 2 weeks prior. In other words, instead of titrating to the onset of damage to vestibular system (as is done for high-dose ITG/TTG), the criterion is a good effect on the disease. This simple idea seems to result in far better results. Occasionally a 3rd dose is given. Usually this results in complete vestibular loss (i.e. see below).



Unilateral loss on right side after 3 injections of gentamicin.

Results of the low-dose gentamicin variant

In [our practice in Chicago](#), we have had excellent results with the low-dose variant, with excellent control of dizziness (100% so far) with no hearing damage at all. Here are what others have reported:

A single dose treatment was reported by at the Mayo clinic, with 84% response rate of vertigo, and no change in hearing. (Driscoll et al, 1997; Harner et al, 2001) These results are attributed to claims that gentamicin destroys the endolymph secreting dark cells before destroying the sensory vestibular epithelium (Beck, 1978). Against this idea is the lack of a pathological change in dark cells after treatment with intravenous aminoglycosides (Cureoglu et al, 2003). The main alternative to the mechanism being destruction of dark cells is the hypothesis that there is a partial damage to the vestibular hair cells. Recent studies in animals suggest that the type-I hair cells are the most sensitive, and the type-II hair cells are more resilient.

A somewhat old meta-analysis (Chia, Gamst et al. 2004) reported that low-dose methods have significantly poorer vertigo control (66.7% overall). This has not been our experience.

Usually, our patients have durable results for dizziness control. For example, we got this email (in 2013):

"Hello, Dr. Hain, Today marks my 5 year anniversary since receiving a gent injection in my left ear. I have been essentially free of all vertigo. So I think we can say that this has been a complete success. Thought I'd let you know the good news."

Although it does seem reasonable that the low dose protocol might have more recurrence (at 1 year+), it is very easy to get another "touch up" injection at 1-2 years, but it is impossible to get one's hearing back after it has been damaged by the more intense protocol.

The long-term results of hearing is unclear at this writing. If low-dose does indeed reduce pressure in the inner ear, it may be that hearing will deteriorate to a lesser extent. At this writing though (2007), this conjecture remains to be proven.

Very low dose -- for older persons

Variant procedures where gentamicin is administered even less frequently than once/month, or in a more dilute solution than is conventional also seem well worth considering. *We routinely recommend use of half-dose gentamicin in persons having this done who are over the age of 70.*

Against this idea is the conjecture that transtympanic gentamicin rapidly "saturates" binding sites in the inner ear, and thus there is no real difference between giving very low dose or low dose -- but rather it is the number of applications of gentamicin that matter, more than the concentration. We don't think that this conjecture is correct, but it would be an interesting project for a researcher to investigate.

The low dose of gentamicin over a prolonged time is likely to have a more uniform effect on the ear than brief, concentrated administrations (Pender, 2003), and also would seem likely to pose much lower risk to hearing.

High dose (or the "scorched earth" protocol):

In the high dose variant, more gentamicin is given over a shorter period of time. This variant works more often (90% of the time), but also is accompanied by far more risk. We call this the "scorched earth" protocol as it seems likely that the "kill" of the inner ear balance hair cells is about 90% for this procedure.

Injections are generally given every week, up to a total of 4-6. The treatment is stopped when vertigo ensues, indicating that the gentamicin is affecting the inner ear. In other words, the treatment is continued until there is evidence of damage to the inner ear.

Rarely, even after 6 injections, vertigo cannot be induced and vestibular function remains normal. At this point, treatment is stopped and another method of eliminating vestibular function is used (such as [labyrinthectomy](#)).

Vertigo usually gets worse for a while: After treatment is stopped, vertigo usually lasts from 7-10 days, but may take as long as a month to resolve. Symptoms are controlled with vestibular suppressants and medications for nausea. Good family support or admission to the hospital is required at this point. Unsteadiness usually resolves after several months, but in older individuals, some unsteadiness may be permanent (although vertigo spells are stopped).

Hearing may worsen after the "scorched earth" protocol. In small mammals, such as guinea pigs, application of gentamicin to the round window area may result in near total loss of hearing (e.g. Imamura et al, 2003). It should be noted, however, that small mammals like this

have much thinner round window membranes than humans, and therefore may get a much larger amount of gentamicin over the same period of time.

Hearing is not nearly as sensitive to gentamicin in humans as animals, but the reason for this is unclear. As protocols evolve, the percentage of treatments associated with hearing reduction continues to gradually be reduced (see table below), but there is still some real risk of hearing loss. A risk of 30% for a mild reduction appears to be "ballpark" at this writing, although recently, better results have been reported (Wu and Minor, 2003).

We believe, based on pharmacokinetic considerations, that protocols where the gentamicin is administered very slowly (i.e. at long intervals) are less risky to hearing than protocols where a large amount of medication is administered over a week or less. If a patient has already lost usable hearing on the "bad" side, then the risk to hearing is eliminated, and either a slow or quick protocol can be used. The "scorched earth" protocol is more sure. The "low dose" protocol is less damaging.

Figure 2: The goal of high dose intratympanic gentamicin treatment is to reduce or eliminate vestibular function from one ear. This causes an imbalance between the two ears, and a spontaneous nystagmus or jumping of the eyes. This figure illustrates a video-eng tracing. Normally, the eyes are still (the trace would be flat)

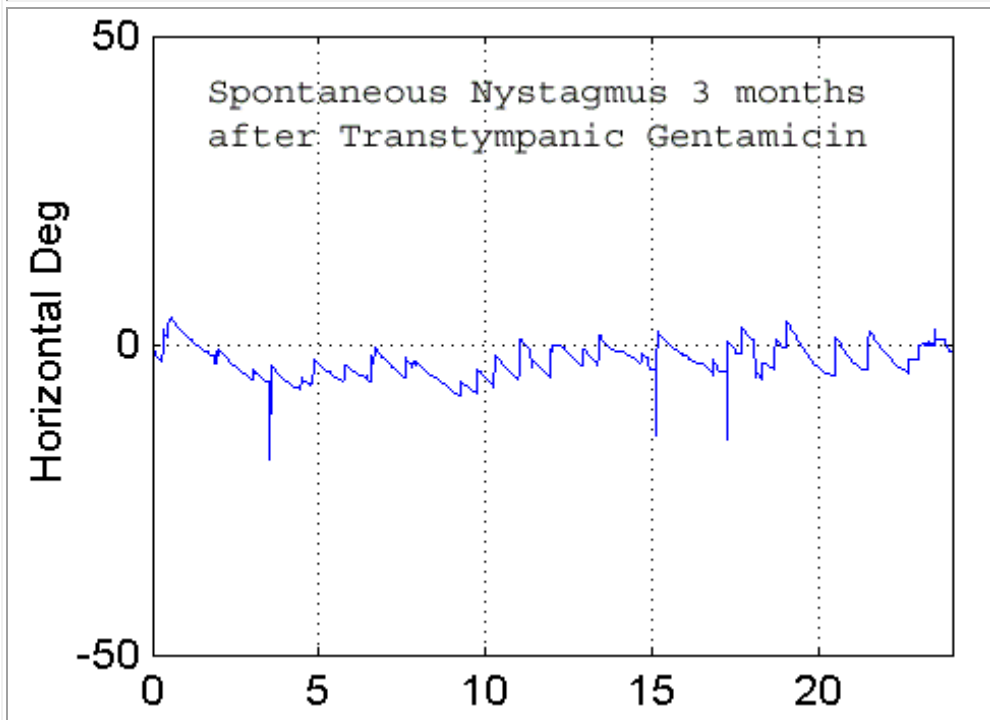


Figure 2 above shows the expected result of high-dose gentamicin -- spontaneous nystagmus and vertigo. This is the hoped for result in a person who has had high-dose gentamicin. We have also noted that all patients with successful low or high-dose gentamicin have strong [vibration induced nystagmus](#).

There is also a movie of something similar in a low-dose protocol patient: [ivg.avi](#) (8 meg)

Nystagmus here is observed 2 weeks after a single dose of intratympanic gentamicin. This is not common, and was an adverse effect of the single dose protocol.

How much damage is done by low dose gentamicin?

The idea of the low-dose protocol is to do a small amount of permanent damage to the ear, just enough to permanently stop vertigo spells. There are naturally no studies of purposeful damage to the ears of normal people. However, we have encountered one patient, who had migraine misdiagnosed as Meniere's, and who had 2 injections of gentamicin. This person developed all of the typical findings of low dose gentamicin (e.g. low amplitude spontaneous nystagmus, vibration induced nystagmus, head-shaking nystagmus). They had an ENG done before and after, showing only about a 10% difference. While it would be improper to generalize from a single case, it does appear that the low-dose protocol does not "wipe out" the inner ear, but rather creates a "partial loss". We usually quote the figure of 25% damage, based on a few patients who have had before/after testing (generally patients with well documented Meniere's).

Results of high dose variant (high dose is not a good idea)

Results, in terms of relief from vertigo, are typically very good (see table). Hearing is generally unaffected or worsened, and may continue to worsen even after vertigo spells are stopped. Tinnitus is also generally unaffected but some recent studies report reduction in tinnitus. Some patients get relief from Meniere's symptoms in spite of a subtotal ablation of vestibular function. This is attributed to selective damage of gentamicin to the dark cells of the labyrinth (Atlas, 1999; Pender, 1985).

In support of this idea is the observation that TTG reduces the size of the summing potential of [ECochG](#), which is a diagnostic test for Meniere's disease (Adamonis et al, 2000). Against this idea is the lack of a change in dark cells after treatment with intravenous aminoglycosides (Cureoglu et al, 2003).

| Authors | number patients treated | response (vertigo) | % hearing reduced | Comment |
|------------------------|-------------------------|--------------------|-------------------|---|
| Schuknecht, 1957 | 5 | 100 | 100 | Treatment with Streptomycin, not Gentamicin |
| Beck and Schmidt, 1978 | 118 | 90 | 58 | |
| Rauch and Oas, 1997 | 21 | 95.2 | 24-38 | 30% relapse rate at 1 year |
| Nedzelski, 1993 | 30 | 100 | 27 | |
| Hirsch, 1997 | 28 | 91 | 33 | |
| Sala T, 1997. | 21 | 86 | 19% | 19% hearing better |
| Micco, 1997 | 10 | 90 | 30 | Weekly Injections |
| Pfleiderer, 1998 | 16 | 87 | 6 | Catheter system used, TID for 4 days. |

| | | | | |
|--------------------------------------|----|--|----------------------------------|---|
| Eklund S, et al, 1999 | 93 | not reported, but presumably very high | 10% deafened. Tinnitus improved. | as many as 10 injections were used |
| Minor, 1999 | 34 | 91% | 3% deafness | 22% recurred |
| Atlas and Parnes, 1999 | 68 | 84-90 | 17% worse, 26% better | Weekly injections |
| Bauer PW, MacDonald CB, Cox LC, 2000 | 6 | "all" | Not relevant | In non-servicable ears |
| Abou-Halawa and Poe, 2002 | 44 | 80% | 14% | One patient deafened |
| (Wu et al. 2003) | 34 | | 17% | 15% hearing improved |
| Perez et al, 2003 | 71 | 83% | 11/71 reduced at 2 years | 27 mg/ml concentration. Treatment ended when signs of vestibular paresis began. 50% loss of caloric function. |
| Flanagan, Mukherjee et al. 2005 | 56 | 83% | 21% | Average loss of 18.5 db |
| Gode et al, 2011 | 25 | good | minimal | VEMPs predict response |
| Olusesi et al. | 9 | "highly effective" | minimal | Used in bilateral menieres, worse ear |
| Watson et al, 2015 | 38 | Good control in 87.7% | No change in 87.5% | A "me too" paper. |

Syed et al (2015) reported that "On the basis of 6 RCT's (n=242) there is evidence to support the effectiveness of intratympanic steroids and gentamicin to control symptoms of vertigo in MS/D albeit with a risk of hearing loss in gentamicin. However, there was no consensus found on doses or treatment protocols. "

We think this conclusion is overly negative -- we think that the low dose gentamicin protocol is reasonably well established in the recent literature.

Other variant intratympanic gentamicin procedures -- generally not good ideas

Before beginning, it should be noted that in the past, most practitioners used the simple protocol of about 4 injections of gentamicin, delivered weekly, stopping when there is signs of damage (this is called titration). This made sense as in a meta-analysis of variant methods was recently reported by Chia and others (Chia, Gamst et al. 2004), the weekly titration method of delivery had the best results with both the best vertigo control and a trend towards less overall hearing loss. However, right now, [in our practice in Chicago](#) as well as in other highly specialized settings, the low-dose protocol has become routine, as we think that it has

even less risk and very good results. Because this procedure works so well, the experiments of the past that we detail below have all become somewhat irrelevant.

Streptomycin: Many other variants of the ITG/TTG protocol have been reported. Streptomycin injection (the dihydro form) has been tried in two published studies (e.g. Schuknecht, 1951), with much worse hearing results than gentamicin. This may be caused by the relative selectivity of gentamicin for the vestibular hair cell, compared to dihydro-streptomycin. It would seem, however, that streptomycin sulfate might be equally effective as gentamicin. There would seem to be little advantage in experimenting with streptomycin as gentamicin works very well without appreciable risk to hearing when given at long intervals.

Streptomycin-dexamethasone: This particular methodology is favored by the "[Shea clinic](#)", an otology practice located in Memphis Tennessee. In our opinion, it is an illogical treatment and it is best avoided. Streptomycin is inferior to gentamicin for this purpose (see above). We also see no logical reason to combine dexamethasone (an intratympanic steroid) with streptomycin (an ototoxic antibiotic). It seems much more logical to us to use these one at a time rather than mixing them together. A discussion of [intratympanic steroids](#) can be found here. Intratympanic steroids are not nearly as effective for Meniere's disease as gentamicin (Gabra and Saliba, 2013), but there are occasions when one does not want to commit quite yet to a "destructive" treatment.

Titration of IT gentamicin:

When to stop treatment is also an issue, especially for the high-dose protocol with weekly injections. Stopping too late might be more toxic to hearing. *Our suggestion is that it is best not to get into this situation in the first place, and use once/month injections.* However, there are sometimes situations where one wants to get a lot of drug in fast, and accept more risk to hearing.

Minor (1999) suggested stopping treatment on appearance of spontaneous nystagmus, head-shaking nystagmus or head-thrust sign. Perez et al (2003) used a similar method. While this protocol appears reasonable to us, it is complex, and stopping simply on a significant change in intensity or direction of spontaneous nystagmus, or till a total of 6 treatments have been delivered might be an adequate substitute. Abou-Halawa and Poe stopped treatment or slowed down treatment when a high-frequency hearing loss appeared. Our thought is that this is much too late as hearing is insensitive to gentamicin. As has been mentioned already - - given the clear superiority of small-dose gentamicin over multiple dose protocols, there no longer seems to be any reason to give more than 1-2 injections, so titration is not really an issue.

In [our practice in Chicago](#), we have had good success in using [vibration induced nystagmus](#) to decide whether or not gentamicin has had an effect. It is a quick and easy method that appears very sensitive to gentamicin. One should see VIN at 1 month in successful injections. This use of VIN is unaccompanied by any published data.

There is literature that supports the idea that VEMP's are reduced or abolished following ITG. A variant of titration method might be to continue injecting until the VEMP is greatly diminished. A problem with this idea is that the injection itself might cause a conductive hearing loss that interferes with the VEMP. As vibration works so well, and we would not

think that someone should be even doing gentamicin injections without the capability to do video-frenzel goggles, this idea doesn't seem to us to be worth pursuing.

Delivery methods:

Numerous methods have been used to deliver gentamicin including direct injection, delivery via a tympanostomy tube, and surgical catheters (Round window m-cath, Durect Corp; Silverstein MicroWick). Either the needle method (low dose) or tympanostomy tube method (high dose where hearing is already gone) seems to work, but there are big differences in cost. *Procedures that require surgical placement of a catheter, at this writing, seem unreasonable as they add risk and cost (the surgery) without better results.*

Procedures that involve placement of a "wick" in the tympanostomy tube (i.e. the "Silverstein MicroWick(tm)"), do not seem very different than simple use of the tympanostomy tube by itself. We do not doubt that it works, but we are not convinced that the additional effort and cost needed to place the special tympanostomy tube and wick as well as it's subsequent removal, is warranted. It is very difficult to compete with the low-dose procedure in terms of results, because they are so good. It is also difficult to understand the rationale of putting in a constant infusion of a drug, when it is well known from animals that gentamicin accumulates in the ear over many months. In this group of patients, better dizziness results are correlated with worse hearing results (Light et al, 2003).

Extra surgery:

Some groups advocate endoscopic exploration of the middle ear and "clearing of adhesions" from the round window niche. It is claimed that adhesions are present in about 20% of round windows. We are dubious that this can be done without additional morbidity to the tympanic membrane (from the endoscope). This procedure also adds a requirement for added cost, specialized equipment and skill to an otherwise rather straightforward procedure. We do not encourage this.

Timing of IT gentamicin:

With respect to timing, protocols that involve rapid administrations of large amounts of drug (here we define rapid as over one week), seem to be prone to produce worse hearing results, possibly because gentamicin has a delayed and prolonged effect, extending over weeks-months, and it is difficult to know if you have given enough or too much, over a week. (Chia, Gamst et al. 2004) However, if hearing is already unusable on the side to be treated, shorter protocols seem quite reasonable.

Finally, some groups suggest [intratympanic dexamethasone treatment](#) -- dexamethasone is a steroid, and not related to gentamicin. At this writing (2/2013), the benefit of this procedure seems to be small -- it may be worth a try in situations where all else has been tried and there is little to lose. Silverstein et al found it to be no better than placebo (1998) For example, it's use might be considered in when the remaining ear affected by Meniere's is the only-hearing ear. It is hard to see how a drug that goes in and out of the ear in 3 days, costs quite a bit to the insurance system, and is associated with significant risks (of perforation) could make much positive difference to a lifelong illness.

Gentamicin vs. steroids vs. vestibular nerve section

There are some complex judgements that come up when one needs to have "something done" about Meniere's disease. Essentially, it comes down to cost vs. benefit

| Method | Hearing Risk | Effectiveness | Durability | Other considerations |
|--|--------------|---------------|-------------------|--|
| Steroid injection | Minimal | Moderate | 3 months | Not a logical treatment as doesn't last |
| Low dose Gentamicin | Minimal | High | Moderate (1-2 yr) | Best choice |
| High dose gentamicin | Moderate | High | Usually permanent | Permanent imbalance not unusual |
| Labyrinthectomy | sure loss | High | Permanent | Permanent imbalance AND hearing loss highly invasive |
| Vestibular nerve section | Moderate | High | Permanent | Permanent imbalance Highly invasive |

In our opinion, low-dose gentamicin is presently the "sweet spot" in this table. We see little reason why any other procedure should be advocated, unless low-dose gentamicin has already failed. The main exception is steroid injection, which does no harm.

Self-administered gentamicin -- usually not a good idea

The simplest procedure (and the least expensive, but you get what you pay for), reported so far is that of Rutka and colleagues (Rutka, 2002). They had simply had the patient administer topical gentamicin themselves through a ventilation tube. A tube is placed in the posterior-inferior quadrant of the TM. Patients are instructed to lie on their side and place 5-6 drops into the affected ear 3 times/day. A low concentration of gentamicin is used -- 3 mg/ml combined with 1mg/ml of betamethasone. This concentration and total dose/day (3 mg) is about 10 times weaker than those used with weekly needle injections (30 mg). They were told to administer the drops until they became constantly vertiginous for 2 days and then stop. Most patients experienced ototoxicity after 12 days of this treatment.

About 50% of patients experienced worsening of hearing and about 40% of patients developed permanent perforations of their eardrums. These results are MUCH WORSE than those associated with single-dose gentamicin. The perforation complication was thought to be a result of the steroid component (Rutka, 2003).

In our opinion, this procedure is less precise than most of the other procedures noted above, and the lack of precision is probably associated with greater hearing risk. Nevertheless, it seems reasonable in situations where hearing is unusable, as an alternative to a surgical labyrinthectomy. As mentioned, it might be preferable to use drops without steroids because of the danger of a permanent perforation. Also, use of less drops per day might result in better hearing results although a longer latency before toxicity begins. We don't think that use of steroids here is a good idea, as it seems to bring on another complication.

Adding other agents to the gentamicin -- also not a good idea

Some groups have experimented with adding other agents to gentamicin, apparently in an attempt to make the solution more viscous and less likely to run down the eustachian tube as soon as the patient sits up. For example, fibrin glue (!?) has been used for this purpose (Casani, Nuti et al. 2005). We do not suggest this procedure. As the problem in the past has mainly been hearing toxicity, procedures that are aimed to increase the dose delivered to the ear would seem irrational unless the ear is already deaf. We are unenthusiastic about the addition of steroids to gentamicin, or steroids to streptomycin (as discussed above).

Why might TTG fail ?

- wrong diagnosis
 - [Migraine](#)
 - Vestibular nerve disorder
 - microvascular compression ([vestibular paroxysmia](#))
 - [Acoustic neuroma](#) or other tumor
 - [Gamma knife](#) treatment of vestibular nerve disorder
 - Poorly defined vertigo syndrome
- bilateral Meniere's disease
- drug delivery failure
 - round window adhesions
 - drug rapidly leaving ear via ET tube
- resistance to gentamicin
 - genetic
- recovery of hair cells

There are a number of reasons why ITG/TTG might fail. First, the diagnosis might be wrong. The patient might have a central disorder (such as [Migraine](#) associated vertigo-- which is at least 25 times more common than Meniere's disease), the patient might have a nerve disorder (such as [microvascular compression](#)), or might have [bilateral Meniere's](#). Disorders of the vestibular nerve would not be expected to respond to TTG.

Ishiyama and associates (2007) reported pathology of the inner ear in a single patient with failed ITG (several attempts), followed by a successful labyrinthectomy. They reported "near complete" ablation of the cristae, and "severe" loss in the utricle. They suggested that potential sources of recurrent vertigo in the patient include the contralateral ear (unlikely as labyrinthectomy worked), the saccule of the ipsilateral side (unlikely that saccule was spared by a drug that affected rest of the inner ear), and the severely damaged utricle (again unlikely). Considering that all of these possibilities are implausible, we would just say that this is difficult to understand and leave it at that.

In patients with bilateral Meniere's, one is more conservative, but nevertheless response has generally been good using "half dose" gentamicin, possibly using more injections (i.e. titration). This good experience is similar to the experience of others, even when they are less cautious than we are (Olusesi et al, 2014).

A second group of reasons depend on the drug not being effective. In theory, it might be ineffective because it isn't delivered to the inner ear (perhaps due to adhesions over the round window, or drug exiting the ear via the eustachian tube), the individual being treated might

have an idiosyncratic resistance to gentamicin ([idiosyncratic susceptibility](#) has been documented, perhaps there is also resistance), or there might be recovery of hair cells that are incompletely damaged. In this regard, initially, gentamicin may do reversible damage to the hair cells. It is common for Meniere's attacks to return 1 or 2 years after the first TTG treatment (Waele et al, 2002). One can be more certain that TTG has killed a significant portion of the inner ear by doing vestibular testing, especially [caloric testing](#). Because of the possibility of reversible damage, one might need to do a caloric about 3 months after the end of treatment (to see the peak response), and do another one if dizziness recurs a year or two later.

In our practice in Chicago, we have occasionally encountered individuals who seem to have "tough" vestibular systems - -they recover function after ablative procedures that would be highly effective in most other patients. We presume that these individuals have a better ability to either adapt to vestibular lesions or recover from them. These people are very rare and do not detract from the general opinions above concerning the very high effectiveness of TTG/ITG.

Patients with **otolithic crises of Tumarkin** (AKA [drop attacks](#), sometimes a variant of [Meniere's](#)) might be thought particularly likely to fail as this is an otolithic disorder, and gentamicin is thought by some to be less toxic to the [otoliths](#) than to the semicircular canals in humans (Ishyama et al, 2007). In our opinion, this is incorrect as recent data (Picciotti et al, 2005; Helling et al, 2007) suggests that gentamicin first affects the saccule (one of the two otolith organs), so the picture may be complex. Abou-Halawa and Poe (2002) reported that of 4 patients with Tumarkin crises, 2 had no further attacks, 1 did not respond, and 1 had a recurrence of attacks requiring additional gentamicin. Our [experience in Chicago](#) has been that TTG/ITG works well for drop attacks.

When TTG fails, careful consideration should be made to exclude failures in the first group (wrong diagnosis). If the diagnosis still appears to be sustainable, then one may wish to consider more radical procedures such as [vestibular nerve section](#) or labyrinthectomy.

We tentatively think that it is a good idea to get a [VEMP](#) prior to ITG/TTG, and another one if there appears to be a treatment failure. This procedure is suggested by Gode et al (2010).

Where to get intratympanic gentamicin treatment

TTG/ITG is an outpatient procedure. Nearly all major medical centers now offer intratympanic gentamicin treatment through their otolaryngology service. In our [dizzy practice in Chicago](#), we can provide this procedure on a one week notice. Before having intratympanic gentamicin treatment, we also think that it is prudent to try all reasonable [medical avenues of treatment](#). Oddly, we have found a few major medical centers, or even entire large metropolitan areas that seem to be unaware of the low dose gentamicin option. *It is best to go somewhere else if your otologist suggests that you will need 4 injections, or wants to repeat the injections in less than 1 month.*

We do not think that one needs to try the [numerous treatments for Meniere's that are probably placebos](#), as these waste time and money, and low-dose gentamicin is very effective. Examples of procedures that are probably placebos or at least only slightly effective, are the Menniett device, [intratympanic steroids](#), and endolymphatic shunt surgery.

Research project ideas

Commercial gentamicin, rather than being a single chemical, actually consists of 3 related compounds. Kobayashi (2008) reported that the 3 compounds vary in their toxicity to the inner ear. It would be interesting to know if use of the compound that is most vestibulotoxic might cause better results than the mixture of compounds. It would also be interesting to know if different drug companies versions of gentamicin vary in their composition.

References related to intratympanic gentamicin treatment:

- Abou-Halawa AS, Poe DS. Efficacy of increased gentamicin concentration for intratympanic injection therapy in Meniere's disease. *Otol Neurotol* 23:494-503, 2002
- Adamonis J and others. Electrocochleography and gentamicin therapy for meniere's disease: a preliminary report. *Am. J. Otol* 21:534-542, 2000
- Bauer PW, MacDonald CB, Cox LC. Intratympanic gentamicin therapy for vertigo in nonserviceable ears. *Am J Otolaryngol* 2001 Mar-Apr;22(2):111-5
- Beck C, Schmidt CL (1978) Ten years experience with intratympanically applied Streptomycin (gentamicin) in the therapy of morbus Meniere. *Arch Otolaryngol* 221, 149-152
- Blakely BW. Clinical Forum: A review of intratympanic therapy. *Am J. Otol*, 18:520-526, 1997
- BOTTRILL I, Wills AD, Mitchell AL. Intratympanic gentamicin for unilateral Meniere's disease: results of therapy. *Clin Otolaryngol* 2003; 28: 133-41
- Brandtberg K, bergenius J, Tribukait A. Gentamicin treatment in peripheral vestibular disorders other than meniere's disease. *ORL* 1996;58:277-279
- Casani, A., D. Nuti, S. S. Franceschini, et al. (2005). "Transtympanic Gentamicin and Fibrin Tissue Adhesive for Treatment of Unilateral Meniere's Disease: Effects on Vestibular Function." *Otolaryngol Head Neck Surg* 133(6): 929-35.
- Chia, S. H., A. C. Gamst, J. P. Anderson, et al. (2004). "Intratympanic gentamicin therapy for Meniere's disease: a meta-analysis." *Otol Neurotol* 25(4): 544-52.
- Cureoglu S and others. Effect of parenteral aminoglycoside administration on dark cells in the crista ampularis. *Arch Otol HNS* 2003;129: 626-628
- Driscoll CL, Kasperbauer JL, Facer GW, Harner SG, Beatty CW. Low-dose intratympanic gentamicin and the treatment of Meniere's disease: preliminary results. *Laryngoscope* 107(1):83-9, 1997
- Eklund and others. Effect of intratympanic gentamicin on hearing and tinnitus in Meniere's disease. *Am J. Otol* 20:350-356, 1999
- Flanagan, S., P. Mukherjee and J. Tonkin (2005). "Outcomes in the use of intratympanic gentamicin in the treatment of Meniere's disease." *J Laryngol Otol*: 1-5.
- Gabra N, Saliba I. The Effect of Intratympanic Methylprednisolone and Gentamicin Injection on Meniere's Disease. *Otolaryngol Head Neck Surg*. 2013 Jan 11. [Epub ahead of print].
- Gode S, Celebisoy N, Akyuz A, Gulec F, Karapolat H, Bilgen C, Kirazli T. Single-shot, low-dose intratympanic gentamicin in Ménière disease: role of vestibular-evoked myogenic potentials and caloric test in the prediction of outcome. *Am J Otolaryngol*. 2011 Sep-Oct;32(5):412-6. Epub 2010 Sep 18.
- Hanson HV (1951). The treatment of endolymphatic hydrops (Meniere's disease) with Streptomycin . *Ann ORL* 60, 676-691
- Harner, S. G., C. L. Driscoll, et al. (2001). Long-term follow-up of transtympanic gentamicin for Meniere's syndrome. *Otol Neurotol* 22(2): 210-4.

- Helling K, Schönfeld U, Clarke AH. Treatment of Ménière's Disease by Low-Dosage Intratympanic Gentamicin Application: Effect on Otolith Function. *Laryngoscope*. 2007 Sep 28;
- HOFFER ME, Allen K, Kopke RD, Weisskopf P, Gottshall K, Wester D. Transtympanic versus sustained-release administration of gentamicin: kinetics, morphology, and function. *Laryngoscope* 2001; 111: 1343-57.
- Ishiyama, G., et al. (2007). "Histopathology of the vestibular end organs after intratympanic gentamicin failure for Meniere's disease." *Acta Otolaryngol* 127(1): 34-40.
- Kobayashi, M., et al. (2008). "Comparisons of cochleotoxicity among three gentamicin compounds following intratympanic application." *Acta Otolaryngol* 128(3): 245-249.
- Mirofuschi T, Halmagyi GM, Yavor RA. Intratympanic gentamicin in Meniere's disease: results of therapy. *Am. J. Otol.* 18:52-7, 1997
- Hirsch BE, Kamerer DB. Intratympanic gentamicin treatment for Meniere's disease. *Am J. Otol*, 18:44-51, 1997
- Laitakari K (1990). Intratympanic gentamicin in severe Meniere's disease. *Clin Otolaryngol* 15, 545-548
- Light JP. Gentamicin perfusion vestibular response and hearing loss. *Otol Neurotol* 24;294-298, 2003
- Magnusson M, Pagdan S, Karlberg M, Johansson R.(1991) Delayed onset of ototoxic effects of Gentamicin in treatment of Meniere's disease. *Acta Otolaryngol (Stockh)* 481 (Suppl) 610-612.
- Minor LB. Intratympanic gentamicin for control over vertigo in Meniere's disease: vestibular signs that specify completion of therapy. *Am J. Otolology*, 20, 2, 1999
- Nedzelski JM, Bryce GE, Pfliegerer AG. Treatment of Meniere's disease with topical Gentamicin: a preliminary report. *J. Otolaryngol* 21, 95-101
- Nedzelski JM, Chong CM, Fradet G, et al. Intratympanic gentamicin installation as treatment of unilateral Meniere's disease: update of an ongoing study. *Am J. Otol* 14,278-282
- Obholzer RJ, Wareing MJ. Intratympanic gentamicin for Meniere's disease; a survey of current UK practice. *J Laryngol Otol* 2003 Jun;117(6):459-61
- Odkvist LM (1988) Middle ear ototoxic treatment for inner ear disease. *Acta Otolaryngol (Stockh)* 457 (Suppl), 83-86
- Odkvist LM, Bergholtz LM, Lundren A (1984) Topical gentamicin therapy for disabling Meniere's disease. *Acta Otolaryngol (Stochk)* 412 (Suppl), 74-76
- Olusesi AD1, Hassan SB, Oyeyipo Y, Ukwuije UC, Oyeniran O. Chemical labyrinthectomy for the worse ear of adult Nigerians with bilateral Meniere's disease: preliminary report of treatment outcomes. *Eur Arch Otorhinolaryngol*. 2014 Feb 26. [Epub ahead of print]
- Pender DJ. Gentamicin tympanoclysis: effects on the vestibular secretory cells. *Am J. Otol* 1985;6:358-67
- Pender DJ Gentamicin tympanoclysis: effects on the labyrinthine sensory cells. *Laryngoscope* 2003 Feb;113(2):343-8
- Perez N, Pastor MJ, Garcia-Tapia R. Assessment of impairment, disability and handicap after Meniere's disease treatment with intratympanic gentamicin. *ARO abstracts* 1999, #784
- Perez N, Martin E, Garcia-Tapia R. Intratympanic Gentamicin for Intractable Meniere's Disease. *Laryngoscope* 2003 Mar;113(3):456-64

- Pflieger AG, The current role of local intratympanic Gentamicin therapy in the management of Meniere's disease. *Clin Otolaryngol* 1998, 23, 34-41
- Picciotti PM, Fiorita A, Di Nardo W, Quaranta N, Paludetti G, Maurizi M. VEMPs and dynamic posturography after intratympanic gentamycin in Menière's disease.1: *J Vestib Res.* 2005;15(3):161-8.
- Plontke SKR, Wood AW, Salt AN. Analysis of gentamicin kinetics in fluids of the inner ear with round window administration. *Otol Neurotol* 23:967-974, 2002
- Rauch SD, Oas JG. Intratympanic gentamicin for treatment of intractable Meniere's disease: a preliminary report. *Laryngoscope* 107(1):49-55, 1997
- Rutka J. update on topical ototoxicity in chronic suppurative otitis media. *ENT Journal supplement* 1, 81:#8, 2002, p18-19
- Rutka J. Aminoglycoside-containing eardrops: avoiding ototoxicity and choosing safer alternatives. *ENT Journal*, 2003, Suppl2, 9-12
- Sala T. Transtympanic gentamicin in the treatment of Meniere's disease. *Auris, Nasus, Larynx* 24(3):239-46, 1997
- Schuknecht HF. Ablation therapy in the management of Meniere's disease. *Acta Otolaryngol* 132 (suppl),1-42, 1957
- Silverstein H. Use of a new device, the MicroWick(tm) to deliver medication to the inner ear. *ENT Journal* 1999, 79, #8
- Silverstein H and others. Dexamethasone inner ear perfusion for the treatment of Meniere's disease: A prospective, randomized double-blind crossover trial. *Am J. Otol.* 19:196-201, 1998
- Soderman AC and others. Patients' subjective evaluations of quality of life related to disease-specific symptoms, sense of coherence and treatment in Meniere's disease. *Otol Neurotol* 22: 526-533, 2001
- Syed MI, Ilan O, Nassar J, Rutka JA. *Clin Otolaryngol.* Intratympanic therapy in Meniere's syndrome or disease: up to date evidence for clinical practice.2015 Apr 27. doi: 10.1111/coa.12449. [Epub ahead of print]
- Yamasaki T, Hayashi M, Hayashi N, Kozaki H (1988) Intratympanic gentamicin therapy for Meniere's disease placed by tubal catheter with systemic isosorbide. *Arch Otorhinolaryngol*, 245, 170-174
- Waele C and others. Intratympanic gentamicin injections for Meniere disease. *Neurology* 2002;59:1442-1444
- Watson GJ1, Nelson C2, Irving RM1. Is low-dose intratympanic gentamicin an effective treatment for Ménière's disease: the Birmingham experience. *J Laryngol Otol.* 2015 Sep 2:1-4. [Epub ahead of print]
- Wu IC, Minor LB. Long-Term Hearing Outcome in Patients Receiving Intratympanic Gentamicin for Meniere's Disease. *Laryngoscope* 2003 May;113(5):815-20